

ONLINE FIRST

Treatment of Tattoos With a Picosecond Alexandrite Laser

A Prospective Trial

Nazanin Saedi, MD; Andrei Metelitsa, MD, FRCPC; Kathleen Petrell, BS; Kenneth A. Arndt, MD; Jeffrey S. Dover, MD, FRCPC

Objective: To study a picosecond 755-nm alexandrite laser for the removal of tattoos to confirm the efficacy of this therapy, focusing on the effect of therapy on the target lesion as well as the surrounding tissues and quantifying the number of necessary treatments.

Design: Fifteen patients with tattoos were enrolled. Treatments were scheduled approximately 6 ± 2 weeks apart. Standard photographs using 2-dimensional imaging were taken at baseline, before each treatment, and 1 month and 3 months after the last treatment.

Setting: Dermatology clinic at SkinCare Physicians in Chestnut Hill, Massachusetts.

Patients: Fifteen patients with darkly pigmented tattoos.

Main Outcome Measures: Treatment efficacy was assessed by the level of tattoo clearance in standard photographs. These photographs were assessed by a blinded physician evaluator and based on a 4-point scale. Efficacy

was also assessed based on physician and patient satisfaction measured on a 4-point scale.

Results: Twelve of 15 patients with tattoos (80%) completed the study. All 12 patients obtained greater than 75% clearance. Nine patients (75%) obtained greater than 75% clearance after having 2 to 4 treatments. The average number of treatment sessions needed to obtain this level of clearance was 4.25. All 12 patients (100%) were satisfied or extremely satisfied with the treatment. Adverse effects included pain, swelling, and blistering. Pain resolved immediately after therapy, while the swelling and blistering resolved within 1 week. Hypopigmentation and hyperpigmentation were reported at the 3-month follow-up.

Conclusion: The picosecond 755-nm alexandrite laser is a safe and very effective procedure for removing tattoo pigment.

Arch Dermatol.

Published online September 17, 2012.

doi:10.1001/archdermatol.2012.2894

Author Affiliations: SkinCare Physicians, Chestnut Hill, Massachusetts (Drs Saedi, Arndt, and Dover and Ms Petrell); Institute for Skin Advancement, Calgary, Alberta, Canada (Dr Metelitsa); Division of Dermatology, University of Calgary, Calgary (Dr Metelitsa); Harvard Medical School, Boston, Massachusetts (Dr Arndt); Brown Medical School, Providence, Rhode Island (Drs Arndt and Dover); Yale University School of Medicine, New Haven, Connecticut (Dr Dover); and Dartmouth Medical School, Hanover, Massachusetts (Dr Dover).

LASERS WERE FIRST USED TO treat tattoos in the 1960s.¹ The use of quality-switching lasers (also known as Q-switching or QS lasers) beginning in the 1980s revolutionized the way tattoos and pigmented lesions were treated and became the gold standard treatment for tattoo removal.² To achieve selective photothermolysis, sufficient energy to damage the target needs to be delivered with a pulse duration that is less than the thermal relaxation time of the target, which is itself defined by the size and shape of the target.³ The smaller the target, the shorter the thermal relaxation time and therefore the shorter the laser pulse duration required.

The thermal relaxation time of tattoo pigment particles and melanosomes is less than 10 nanoseconds, suggesting that en-

ergy delivery in the picosecond range (1 trillionth of a second, 10^{-12} seconds) should be effective.⁴⁻⁶ Picosecond laser treatments cause significant photomechanical effects and lead to mechanical breakup of the ink or pigment particles. Using picosecond pulses allows lower treatment fluences to be used, which should decrease adverse effects while keeping the peak tensile stress induced substantially higher than that typically produced with QS lasers (nanosecond duration, 10^{-9} seconds)—an ideal combination of higher efficacy and less adverse reactions. In this study, a 755-nm picosecond alexandrite laser (Cynosure), a wavelength is well absorbed by dark tattoo pigment, was used to treat tattoos. The purpose of the study was to assess the results of picosecond tattoo treatment, focusing on time to clearance, adverse effects, and the num-

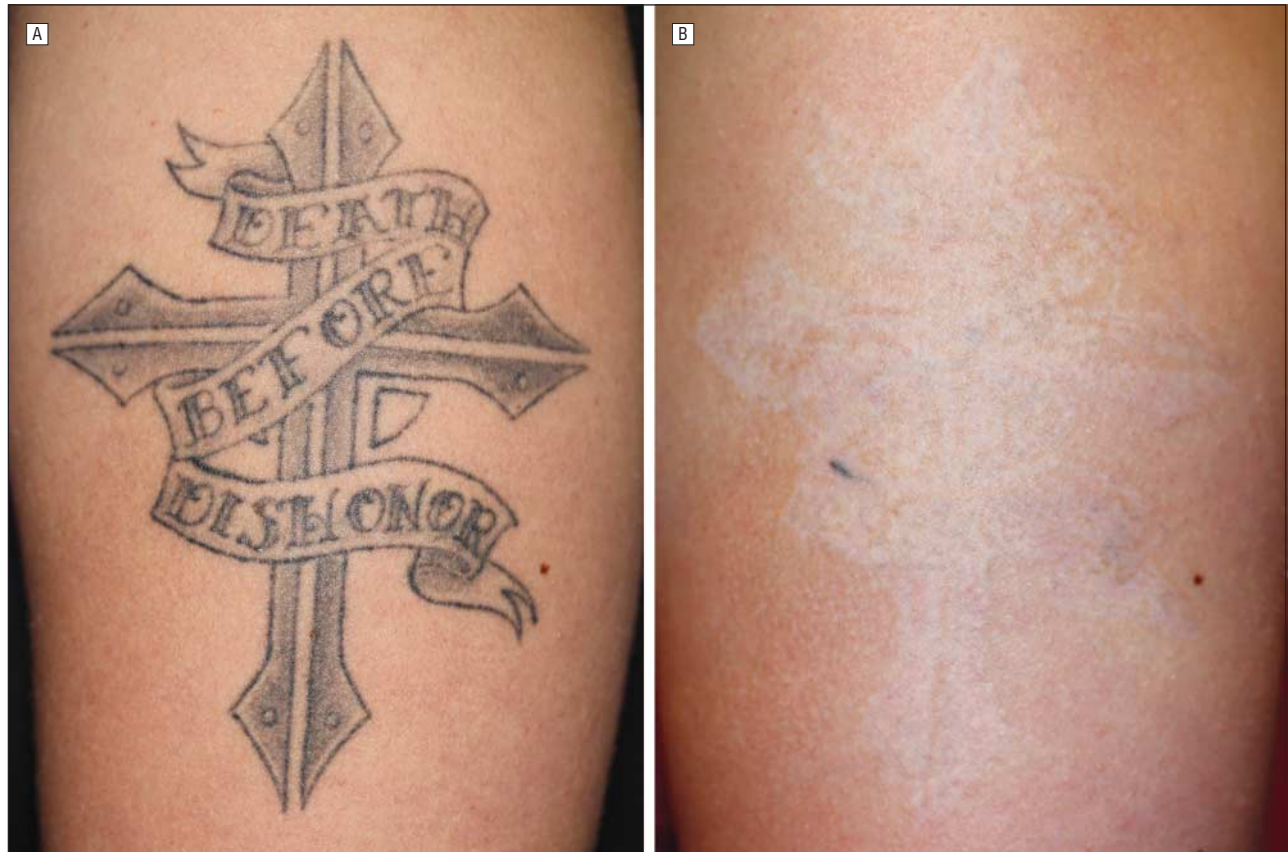


Figure 1. Tattoo treatment. A, Prior to treatment the tattoo consist of a single dark color, which is ideal for treatment. B, After 4 treatments delivered over 4 months, there was greater than 75% clearance.

ber of treatments to clearing compared with historical controls.

METHODS

This was a single center, prospective study approved by the New England institutional review board that was performed from November 2009 through September 2011. The study enrolled patients ages 19 to 76 years with Fitzpatrick skin types I to V with darkly pigmented tattoos (black or blue). Exclusion criteria included hypersensitivity to light exposure, active or systemic infections, active medications for which sunlight is a contraindication, history of squamous cell carcinoma or melanoma, history of keloid scarring, use of oral isotretinoin within 12 months prior to the treatment, and history of immunosuppression. In addition, pregnant women were excluded, along with those who were pregnant 3 months prior or breastfeeding.

Standard photographs using 2-dimensional imaging were taken at baseline, before each treatment, and 1 month and 3 months after the last treatment. The treatments were repeated at an interval of 6 ± 2 weeks, up to a maximum of 10 treatments. Treatments were performed with the 755-nm picosecond alexandrite laser (Cynosure). Single treatments with one pass were performed using an energy of 150 to 200 mJ (2.1 to 4.1 J/cm²), pulse duration of 500 to 900 picoseconds, spot size from 2.5 to 3.5 mm, and a repetition rate of 5 Hz. Treatment parameters were selected based on the patient's skin type and achievement of clinical end point (whitening) during the initial test spot. Patients were offered a topical or injectable anesthetic during therapy. Protective eyewear was properly placed on the patient, and appropriate goggles were worn by the treat-

ing physician. Necessity of further treatment was dependent on the rate of clearance of the lesion and the physician's discretion. After each treatment, the patient was asked to rate the pain on a 10-point scale (1=no pain, 10=worst pain).

Three months after the last treatment, efficacy was assessed by physician, and patient was satisfaction based on a 4-point scale (0=extremely dissatisfied; 1=dissatisfied; 2=satisfied; 3=extremely satisfied). Efficacy was also assessed by the level of tattoo clearance in standard photographs that were taken at each visit. These photographs were assessed by a blinded physician evaluator and based on a 4-point scale ($0 \leq 25\%$, $1 = 26\% - 50\%$, $2 = 51\% - 75\%$, and $3 \geq 75\%$). A 1-week diary was given to patients after the first treatment to record adverse effects. Adverse events were also recorded by the treating physician.

RESULTS

Fifteen patients with tattoos enrolled in the study, and their ages ranged from 19 to 76 years (mean, 43.7 years). Ten women (67%) and 5 men (33%) were treated. Fitzpatrick skin types I through V were treated, with most of the patients (67%) having skin types II and III.

Twelve of 15 (80%) patients completed the study. Three patients completed 1 treatment but were not able to return for further treatments and follow-up. The photographs that were taken at each visit were evaluated by the blinded physician evaluator to determine the level of tattoo clearance. Twelve patients (100%) had tattoo clearance of greater than 75%, and 9 (75%) obtained greater than 75% clearance after 2 to 4 treatments

(**Figure 1** and **Figure 2**). The average number of treatment sessions to obtain greater than 75% clearance was 4.25 (**Table**).

The procedure was well tolerated with minimal subsequent downtime. The patients reported a mean (SD) pain score of 4.5 (2.69) based on a 10-point pain score (1 = no pain, 10 = worst pain). None of the patients received injectable anesthesia, and only 2 (13%) received topical 30% lidocaine (applied over the treatment area for 30 minutes prior to treatment). The patients who re-

ceived topical anesthesia reported pain scores of 1 to 3. Postinflammatory hypopigmentation 3 months after the last treatment was observed in 3 patients (20%) and hyperpigmentation was observed in 2 patients (13%).

Physician and patient satisfaction was high and correlated with level of clearance. All of the patients (12) rated themselves satisfied or extremely satisfied after their treatments. The blinded physician evaluator was also satisfied or extremely satisfied for all of the patients (12).

COMMENT

In this study, the picosecond 755-nm alexandrite laser was found to be very effective in treating tattoos. The picosecond pulse duration is approximately 100 times shorter than the commercially available QS laser pulses and closer to the thermal relaxation time for tattoo pigment. For best results, the energy should be delivered within a pulse that most closely matches the thermal relaxation time of the pigmented tattoo particle, which ranges from 40 to 300 nm.⁶ Most of these particles have thermal relaxation times in the picosecond range, estimated to range from 10.12 to 1060 picoseconds.⁶

Ross et al⁴ and Herd et al⁵ were the first to study the effect of a picosecond laser to effectively target tattoo pigment. Ross et al compared picoseconds and nanosecond pulses on 16 black tattoos in human patients using a 1064-nm Nd:YAG laser.⁴ The parameters consisted of a fluence of 0.65 J/cm², spot size of 1.4 mm, and a pulse duration of either 35 picoseconds or 10 nanoseconds. After 4 laser treatments at 4-week intervals, the picosecond pulses showed greater lightening in 12 of 16 patients without any adverse effects.

Herd et al⁵ compared the efficacy of picosecond titanium:sapphire (795 nm, 500 picoseconds) laser with that of the Q-switched alexandrite (755 nm, 50 nanoseconds) laser in the treatment of tattooed guinea pigs. Six albino guinea pigs, each with uniform, 1-cm circular black tattoos, were treated. Three of the tattoos were divided in half, with 1 side treated using the titanium:sapphire picosecond laser and the other side treated with the QS alexandrite laser. The parameters used for both lasers were

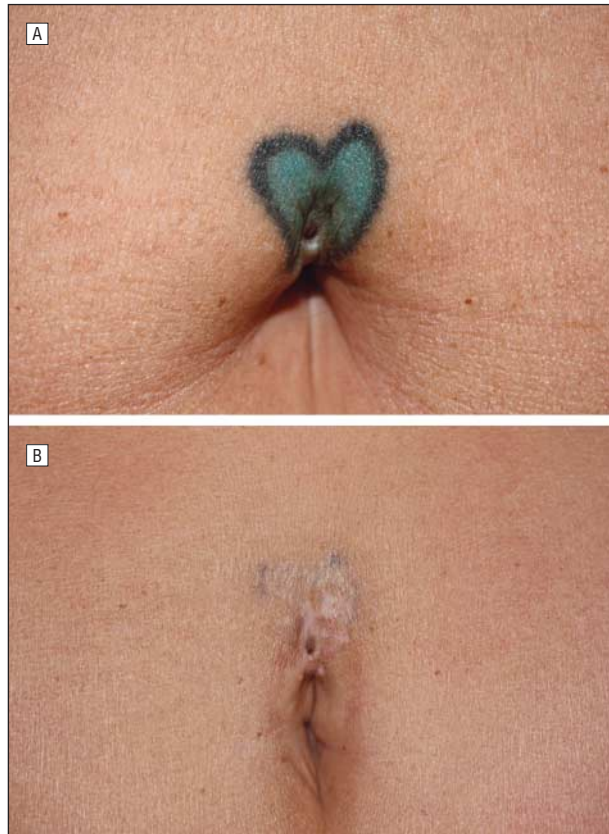


Figure 2. Tattoo treatment. A, Prior to treatment, this tattoo consisted of 2 dark colors and was designed to conceal a scar. B, After 4 treatments delivered over 4 months, there was greater than 75% clearance.

Table. Tattoo Population and Summary of Results

Patient No./Age, y	Fitzgerald Skin Type	Tattoo		Treatments, No.	Clearance, %
		Location	Color		
2/40	3	Left shoulder	Black	6	>75
3/45	3	Abdomen (above umbilicus)	Blue, black	4	>75 (AC)
7/31	3	Lower back	Blue, black	4	>75
8/54	3	Lower back	Black	6	>75
9/31	4	Right upper arm	Black	10	>75 (AC)
10/27	2	Left chest	Black	3	>75
11/53	2	Right upper arm	Black	3	>75 (AC)
12/21	2	Left upper arm	Black	2	>75 (AC)
13/52	3	Right forearm	Blue	2	>75 (AC)
14/48	1	Mid chest	Blue	3	>75 (AC)
15/40	5	Left chest	Black	4	>75
21/43	1	Right lower back	Black	4	>75 (AC)

Abbreviation: AC, almost complete.

fluences of 6.11, 4.24, and 2.39 J/cm² with spot sizes of 1.25, 1.5, and 2 mm, respectively. Greater clearance of the tattoo was observed in the areas treated with the titanium:sapphire laser and in areas treated with higher energies without any adverse events.

More recently, Izikson et al⁶ compared a novel 758-nm alexandrite 500-picosecond laser with a QS alexandrite laser for treating black carbon tattoos in an animal model (Yorkshire pig). The 758-nm picosecond laser was used in 3 settings to produce tissue whitening: high (13-16 J/cm², 1.3-mm spot size), medium (6-7.5 J/cm², 1.9-mm spot size), and low (2.5-3.9 J/cm², 2.9-mm spot size). The setting used for the 755-nm QS alexandrite laser was a fluence of 8 J/cm², spot size of 3 mm, and a pulse duration of 30 to 50 nanoseconds. After a single treatment, the 758-nm 500-picosecond laser produced greater tattoo clearance at all the tested fluencies than the QS alexandrite 755-nm laser.

Our study used a picosecond alexandrite laser that is pending commercial availability. While there was no control group in this study, we used historical controls to assess the comparative efficacy of the picosecond laser device. Fitzpatrick and Goldman⁷ were the first to evaluate the effectiveness of the QS alexandrite laser in removing darkly pigmented (black and bluish-black) professional and amateur tattoos. Seventeen patients with professional tattoos and 8 patients with amateur tattoos were treated with the QS alexandrite (755 nm, 4-8 J/cm², 3 mm, 100 nanoseconds) at monthly intervals. Twenty patients (87%) had greater than 95% of tattoo pigment clearance after an average of 8.9 treatment sessions. Transient hypopigmentation occurred in 50% of patients and transient textural alteration occurred in 12% of patients, but there were no long-term pigmentary or textural changes. Alster⁸ also evaluated the clinical effectiveness of the QS alexandrite in eliminating amateur and multicolored professional tattoos. Twenty-four multicolored professional tattoos and 18 bluish-black amateur tattoos were treated with the QS alexandrite laser (755 nm, 4.75-8 J/cm², 3 mm, 100 nanoseconds) at 2-month intervals until total clearance was obtained. There was no scarring and no long-standing pigmentary change. The professional tattoos required an average of 8.5 treatments for total clearance, and the amateur tattoos required an average of 4.6 treatments. Both studies had a similar average number of treatment sessions needed for tattoo clearance.

In the studies using the QS alexandrite laser, an average of 8.9 and 8.5 treatment sessions were needed to obtain greater than 95% clearance in tattoo pigment,^{7,8} whereas with the picosecond alexandrite laser in our study, an average of 4.25 treatment sessions were needed to obtain greater than 75% clearance. Although the maximum scoring in this study was greater than 75% clearance, most patients (58%) had almost complete clearance of the tattoo as assessed by the blinded physician evaluator (Table). Prospective, controlled, and blinded

studies are needed to further assess the relative efficacy of picosecond and nanosecond QS lasers.

The picosecond 755-nm alexandrite laser is a safe and very effective device for tattoo removal and seems to clear pigment in tattoos more rapidly than QS lasers. Picosecond lasers are an emerging technology that has the potential to optimize the treatment of tattoos.

Accepted for Publication: June 19, 2012.

Published Online: September 17, 2012. doi:10.1001/archdermatol.2012.2894

Correspondence: Nazanin Saedi, MD, SkinCare Physicians, 1244 Boylston St, Ste 103, Chestnut Hill, MA 02467 (nsaedi@gmail.com).

Author Contributions: All authors had access to all the data in the study and take responsibility for the integrity of the data and the accuracy of the data analysis. *Study concept and design:* Petrell, Arndt, and Dover. *Acquisition of data:* Saedi, Metelitsa, Petrell, Arndt, and Dover. *Analysis and interpretation of data:* Saedi, Metelitsa, and Arndt. *Drafting of the manuscript:* Saedi and Dover. *Critical revision of the manuscript for important intellectual content:* Saedi, Metelitsa, Petrell, Arndt, and Dover. *Statistical analysis:* Saedi. *Obtained funding:* Dover. *Administrative, technical, and material support:* Metelitsa, Petrell, Arndt, and Dover. *Study supervision:* Arndt and Dover.

Financial Disclosure: Drs Metelitsa and Dover serve as consultants to Cynosure. Dr Dover has received research grants from Cynosure.

Funding/Support: This study was supported by in part by a research grant from Cynosure.

Role of the Sponsors: The sponsors had no role in the design and conduct of the study; in the collection, analysis, and interpretation of data; or in preparation, review, or approval of the manuscript.

REFERENCES

1. Goldman L, Rockwell RJ, Meyer R, Otten R, Wilson RG, Kitzmiller KW. Laser treatment of tattoos: a preliminary survey of three year's clinical experience. *JAMA*. 1967;201(11):841-844.
2. Taylor CR, Gange RW, Dover JS, et al. Treatment of tattoos by Q-switched ruby laser: a dose-response study. *Arch Dermatol*. 1990;126(7):893-899.
3. Anderson RR, Parrish JA. Selective photothermolysis: precise microsurgery by selective absorption of pulsed radiation. *Science*. 1983;220(4596):524-527.
4. Ross V, Naseef G, Lin G, et al. Comparison of responses of tattoos to picosecond and nanosecond Q-switched neodymium: YAG lasers. *Arch Dermatol*. 1998;134(2):167-171.
5. Herd RM, Alora MB, Smoller B, Arndt KA, Dover JS. A clinical and histologic prospective controlled comparative study of the picosecond titanium:sapphire (795 nm) laser versus the Q-switched alexandrite (752 nm) laser for removing tattoo pigment. *J Am Acad Dermatol*. 1999;40(4):603-606.
6. Izikson L, Farinelli W, Sakamoto F, Tannous Z, Anderson RR. Safety and effectiveness of black tattoo clearance in a pig model after a single treatment with a novel 758 nm 500 picosecond laser: a pilot study. *Lasers Surg Med*. 2010;42(7):640-646.
7. Fitzpatrick RE, Goldman MP. Tattoo removal using the alexandrite laser. *Arch Dermatol*. 1994;130(12):1508-1514.
8. Alster TS. Q-switched alexandrite laser treatment (755 nm) of professional and amateur tattoos. *J Am Acad Dermatol*. 1995;33(1):69-73.